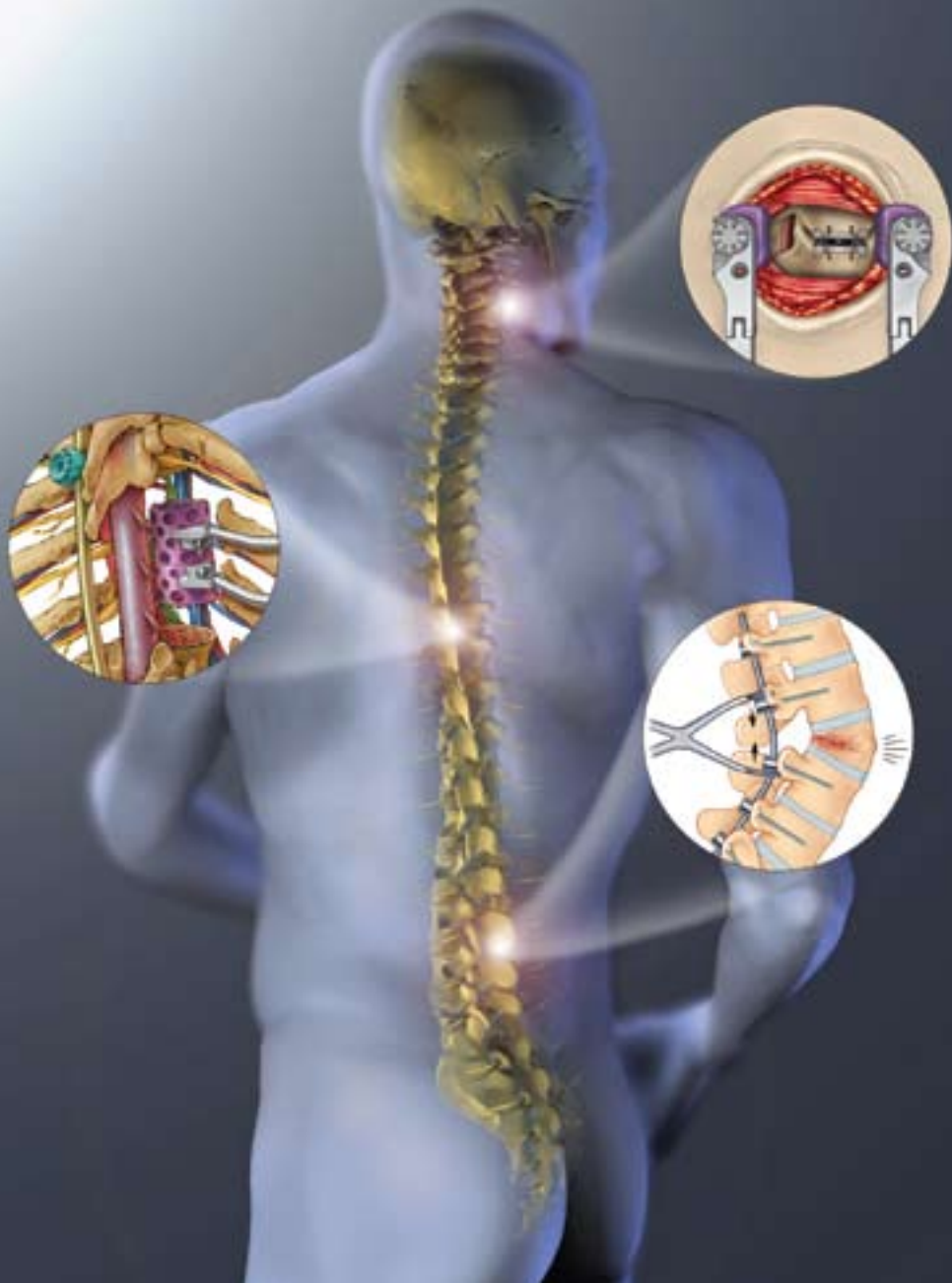

University of California
San Francisco

UCSF

Neurological Surgery

The Neurospinal Disorders Program of the Department of Neurological Surgery at UCSF





Message from the Directors



Christopher Ames, MD



Praveen Mummaneni, MD

The Neurospinal Disorders Program at the University of California, San Francisco (UCSF) provides comprehensive treatment for all pathologies affecting the spine and peripheral nerves. The program is based in the Department of Neurological Surgery and is a component of the UCSF Spine Center. Our neurosurgeons have considerable experience in the evaluation and management of patients with difficult-to-manage or rare spinal disorders, including tumors, severe deformity, degenerative disorders, and traumatic injuries. State-of-

the-art diagnostic and surgical tools are used with the goals of eliminating pain, preventing paralysis, restoring functional capacity, and improving quality of life. With these objectives in mind, we have recently expanded our minimally invasive surgery program, which focuses on outpatient and short-stay spinal surgery. The Neurospinal Disorders Program is also built on a strong foundation of both clinical and laboratory research and we are excited to be leading several new clinical trials of cutting-edge therapies.

While surgery is the mainstay of treatment for debilitating spinal disorders, we apply a multidisciplinary strategy for managing patients. By collaborating with orthopedic surgeons, radiation oncologists, and neuroradiologists at the UCSF Spine Center to form diagnoses and treatment plans, our patients benefit from the expertise of a variety of specialists. We are committed to excellence in patient care, improving current surgical techniques, and providing the most advanced treatment options available to patients with spinal disorders.

Christopher P. Ames
Co-director,
Neurospinal Disorders Program


Department of
Neurological Surgery, UCSF

Praveen V. Mummaneni
Co-director,
Neurospinal Disorders Program

Department of
Neurological Surgery, UCSF



Dean Chou, MD



Philip Weinstein, MD



Nicholas Barbaro, MD

Our Faculty

Christopher P. Ames, MD, is co-director of the Neurospinal Disorders Program, co-director of the UCSF Spine Center, director of Spinal Tumor Surgery, and director of Spinal Deformity Surgery. He is board certified in neurosurgery and was a spine fellow at Barrow Neurological Institute. His clinical practice focuses on complex spinal reconstructive surgery for tumor resection and correction of spinal deformity in all areas of the spinal column, including the occipital cervical junction. He specializes in cases of failed prior surgery and revision operations for failed back syndrome, disc replacement surgery, en bloc resection of primary spinal tumors in all spinal regions, and is one of the only neurosurgeons in the country performing corrective surgery for neuromuscular scoliosis. Dr. Ames is the 2005 winner of the prestigious International Society for Study of the Lumbar Spine research award for his work on spinal fusion in tumor reconstructions requiring radiation therapy. Currently Dr. Ames is the principal investigator in five randomized prospective clinical trials evaluating novel mechanisms of spinal reconstruction in neoplastic and degenerative disease.

Praveen Mummaneni, MD, is co-director of the Neurospinal Disorders Program, co-director of the UCSF Spine Center, co-director of the Spine Fellowship Program, and director of both Minimally Invasive Spine Surgery and Cervical Spine Surgery. Dr. Mummaneni specializes in complex cervical spine surgery, minimally invasive spine surgery, degenerative spine disease, adult spinal deformity, and spinal trauma. He is board certified in neurosurgery and in 2005 he was selected as one of the Best Doctors in America. In 2006, he was the honored guest of the Japanese Congress of Neurological Surgeons. Dr. Mummaneni has completed fellowship training in adult spinal deformity surgery and in minimally invasive spine surgery at Northwestern University and at Emory University. As Director of Minimally Invasive Spine Surgery at UCSF, he is leading a new initiative focusing on outpatient and short-stay spinal surgery.

Dean Chou, MD, completed his residency at Johns Hopkins University and a fellowship in complex spinal surgery at Barrow Neurological Institute. His practice specializes in the treatment of spine tumors, both metastatic and primary. His other areas of expertise include minimally invasive and open techniques to treat complex spinal disorders.

He also uses thoracoscopic techniques to treat diseases of the thoracic spine.

Dr. Chou's research interests are focused on clinical outcomes in spine surgery. He is developing protocols to evaluate the increasing role of surgery compared to other treatment modalities in treating metastatic spine disease. He is also developing protocols to assess the outcomes of minimally invasive spine surgery compared to open procedures.

Philip Weinstein, MD, has been a leader in the treatment of neurospinal disorders at UCSF for the last 25 years. He specializes in the treatment of adult disc disease, adult spinal deformities, spondylolisthesis, spinal stenosis, complex spinal instrumentation, degenerative neurospinal disorders, spinal axis tumors, spinal cord vascular malformations, and spinal trauma or instability. Dr. Weinstein's research has chiefly concerned repair and regeneration after spinal cord injury, the cerebrovascular, cardiovascular, and metabolic aspects of cerebral ischemia, and mechanisms of brain protection during temporary focal ischemia and reperfusion. More recently, he has become involved in molecular biologic approaches to mechanisms of ischemic neuronal injury in the brain and spinal cord and

the study of impairment of blood flow regulation. Among his recent clinical research studies are evaluation of MR neurography, diffusion and CSF-flow MRI of cervical stenosis, intraoperative neurophysiological monitoring, and surgical management of transdural CSF fistulae leading to intracranial hypotension. He is also interested in sacral meningeal cysts and the results of surgery or CyberKnife® radiosurgery for benign nerve sheath tumors.

Nicholas Barbaro, MD, has extensive expertise in the treatment of chronic intractable pain syndromes and performs all nerve surgeries in the Department of Neurological Surgery at UCSF for indications that include nerve injury, peripheral nerve tumors, and entrapment syndromes. He also directs the multidisciplinary UCSF Nerve Injury Clinic, which includes specialists in the fields of neurological surgery, neurology, and orthopedic surgery. The Clinic has grown substantially, provides important training for neurosurgery residents, and is an important community resource. Dr. Barbaro evaluates patients with refractory chronic pain for potential surgical treatment, including spinal cord stimulators, intrathecal infusion pumps, and dorsal root entry lesioning (DREZ).

UCSF neuroradiologists specializing in imaging of the spine and peripheral nerves use advanced techniques for rapid and accurate diagnoses.

- **Computed Tomography (CT):** Six CT scanners provide detail of the bony anatomy of the spinal vertebrae. These scanners are also used for CT angiography, which allows visualization of a patient's disease in relation to the complex vascular structures surrounding the spinal cord. 3D CT reformatting is used to create 3D representations of the spinal anatomy as it would be seen in the operating room, allowing for improved preoperative planning and safer procedures.
- **Magnetic Resonance (MR) Imaging:** Three 3T scanners and nine 1.5T scanners, all

equipped with the most up-to-date software and protocols, produce exquisite detail of the spinal cord, vertebral column, and discs.

- **Functional Imaging:** MR diffusion is an advanced technique that has been widely used in brain imaging, but can now also be applied to the spine. Non-routine sequences are employed to identify common clinical problems of the spinal cord and vertebral column, such as ischemia, myelopathy, injury, and infection.
- **MR Neurography:** MR neurography is a form of tissue-selective imaging directed at identifying and evaluating characteristics of nerve morphology, which may be used for diagnosis of peripheral nerve disorders.

This novel technique offers increased specificity over electrodiagnostic tests and standard MRI by using morphology and signal intensity to distinguish between normal and abnormal nerves.

- **Positron Emission Tomography (PET):** Two PET scanners are used in the diagnosis and management of spinal tumors.

Interventional Neuroradiology

Neuroradiologists perform a wide range of interventional diagnostic and therapeutic procedures, some of which are inherently less invasive and may preclude surgery. Some of these techniques include:

- CT-guided pain procedures
 - Cervical and lumbar nerve, epidural, and facet blocks
 - Sciatic nerve anesthetic injections
 - Piriformis anesthetic injections
 - Radiofrequency ablations
- Discography
- Spinal angiography
- Embolization of spinal vascular malformations
- Vertebralplasty for osteoporotic compression fractures
- Spinal and soft tissue biopsy

Neuroradiology

Deformity

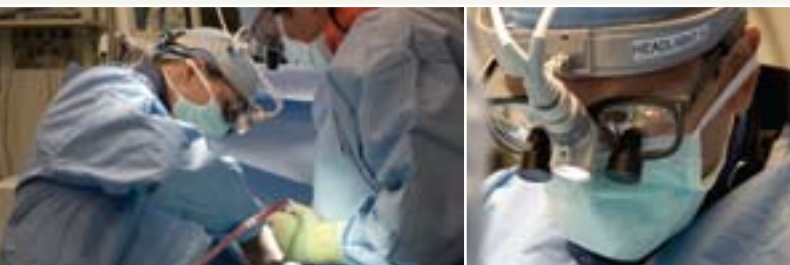The Neurospinal Disorders Program at UCSF provides expert care for all aspects of spinal deformity, including kyphosis, scoliosis, and spondylolisthesis, which may result in acute or chronic instability, neurological deficit, and pain. Our neurosurgeons place particular emphasis on adequate and thorough neural decompression and protection combined with restoration of normal global and regional spinal balance. State-of-the-art spinal-

cord monitoring techniques are employed by PhD-level electrophysiologists in the operating rooms to provide the highest levels of patient safety. Conditions treated include:

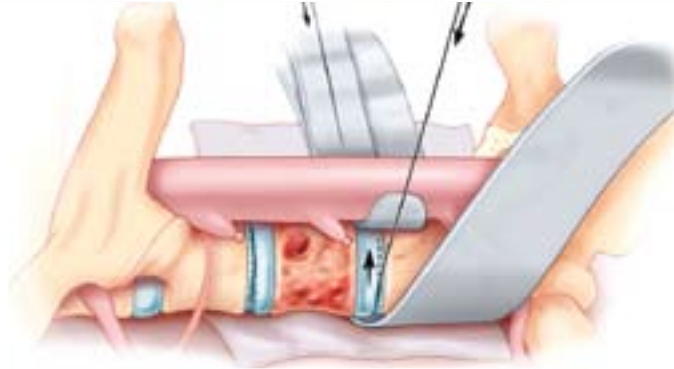
- Adult degenerative scoliosis
- Adult idiopathic scoliosis
- Adolescent scoliosis
- Congenital deformities
- Scheurmann's kyphosis

- Severe lordotic deformities
- Severe kyphotic deformities
- Failed-back syndrome
- Flat-back syndrome
- Chin-on-chest kyphotic deformity
- High-grade spondylolisthesis
- Neuromuscular scoliosis
- Ankylosing spondylitis
- Rheumatoid arthritis

To restore functional capacity and eliminate pain, our skilled team of neurosurgeons uses a wide variety of techniques, including pedicle subtraction osteotomies, Smith-Petersen osteotomies, Ponte-type osteotomies, and vertebral column resection.



En bloc spondylectomy is the best treatment option for a variety of primary spinal tumors. This technique removes the tumor without violating its margins. UCSF is currently the only center in California routinely performing this complex procedure.



Spinal Tumors

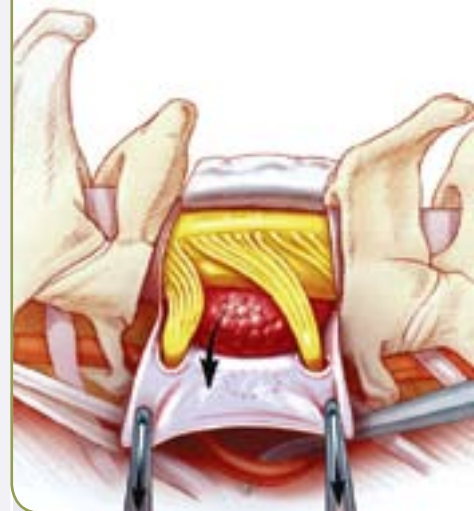The Neurospinal Disorders Program offers treatment for all primary and metastatic tumors from the skull base to the sacrum. Over 150 spine tumor surgeries are performed at UCSF each year and our neurospinal surgeons are continually at the forefront of developing new techniques for optimal resection. The lateral transpedicular approach to deep midline tumors of the cervical spine was developed by Christopher Ames, MD, and allows complete resection of difficult-to-access tumors without spinal cord retraction.

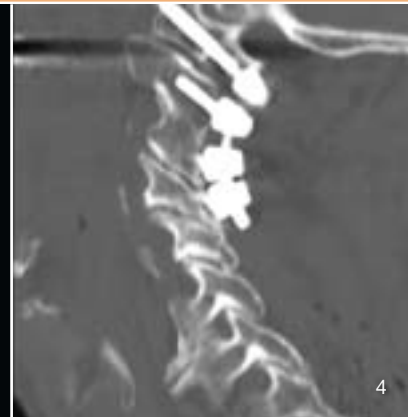
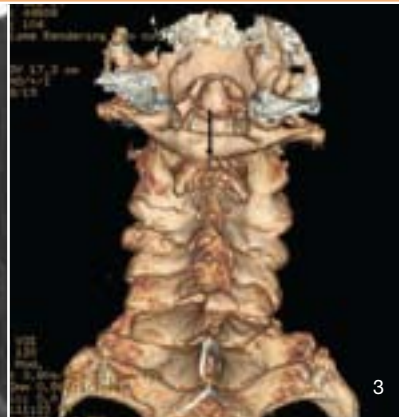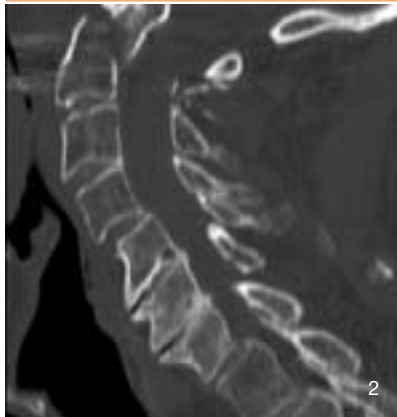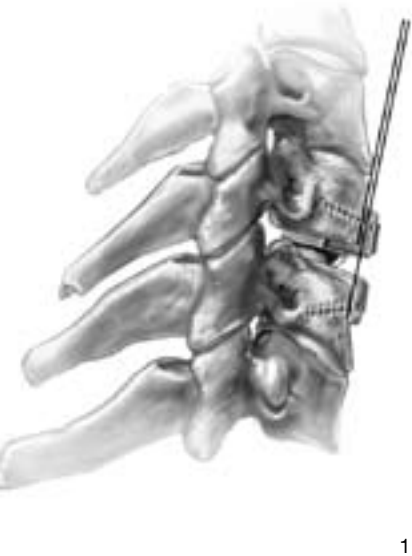The UCSF spine tumor service is the only center on the West Coast routinely performing en bloc surgical resection for primary spinal tumors of all regions of the spinal column and sacrum. Our neurospinal surgeons have special expertise in transpedicular corpectomy for metastatic tumors, sparing many cancer patients from a thoracotomy procedure and resulting in less morbidity and shorter hospital stays. All spine tumor cases are routinely reviewed at a multidisciplinary spine tumor board to determine the best treatment options for each patient.

Surgical Techniques for Removal of Malignant Neoplasms

- En bloc resection for sacral tumors
- Spondylectomy for primary tumors
- Transpedicular corpectomy for metastatic tumors
- Cervical transpedicular technique for ventral intradural tumors

The lateral transpedicular approach with corpectomy essentially delivers tumor out from under the spinal cord without any spinal cord retraction.





1. Illustration of a lateral view of the PRESTIGE ST arthroplasty showing the translation capability of this artificial cervical disc
2. Sagittal CT reconstruction view of C2 dens fracture with posterior C2 element fracture
3. Preoperative 3-Dimensional reconstruction view of vertical fracture through the spinous process of C2 (arrow)
4. Sagittal CT reconstruction view following posterior C1-4 screw and rod fixation

Cervical Spine Disorders

The Occipito-cervical Junction

The occipito-cervical junction of the spine spans from the occiput to C2, and is critical for neck rotation and flexion. Instability in the occipito-cervical junction of the spine can cause severe pain, paralysis, or dysfunction of the cranial nerves. It may result from a wide variety of conditions including rheumatoid arthritis, congenital defects, trauma, tumor, infection, and iatrogenic decompression. The Neurospinal Disorders Program at UCSF uses the latest developments in instrumentation to provide safer and more-effective treatments. The most current systems combine screws, bolts, and plates that provide a much greater degree of rigidity to the occipito-cervical junction than was previously possible.

The C1-2 Junction

C1-2 instability is primarily caused either by rheumatoid arthritis or by previous traumas

or fractures. Our surgeons have substantial experience with advanced procedures and use both transarticular screws and the Harms technique to restore stability to the region. Because it is done under direct visualization of the C1-2 joint, the Harms technique greatly reduces the risk of injuring the vertebral arteries.

The Subaxial Cervical Spine

Consequences of instability to the subaxial cervical spine range from radicular pain (sciatica) to severe damage to the spinal cord, depending on the source. Possible causes of subaxial cervical spine injury include disc herniations, stenosis, bone spurs, or trauma. The Neurospinal Disorders group at UCSF has considerable expertise in both anterior and posterior surgical approaches to treat pathologies of all types and locations.

Anterior Techniques

- Discectomy
- Corpectomy
- Complex reconstruction
- Motion-sparing disc replacement implant technology

Posterior Techniques

- Laminectomy (with or without fusion)
- Laminoplasty
- Laminoforaminotomy
- Minimally Invasive decompression

Minimally Invasive Surgery

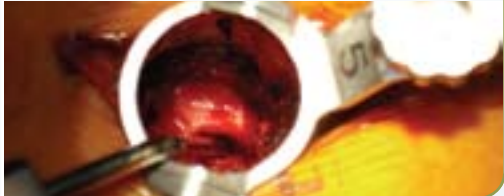
Minimally invasive surgery is available for a number of neurospinal disorders, ranging from degenerative diseases to spinal tumors. These procedures

have potential to greatly benefit patients by reducing surgical risk, pain, blood loss, risk of infection, and time to recovery. Our specialists have extensive

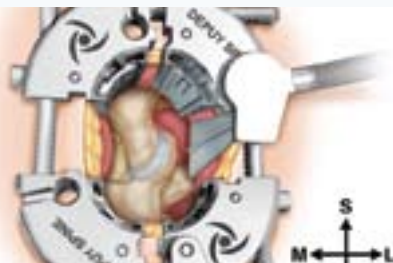training and experience in minimally invasive spinal techniques, some of which can be performed in the outpatient setting.

State-of-the-art instrumentation designed for these procedures allow for improved visualization and mobility.

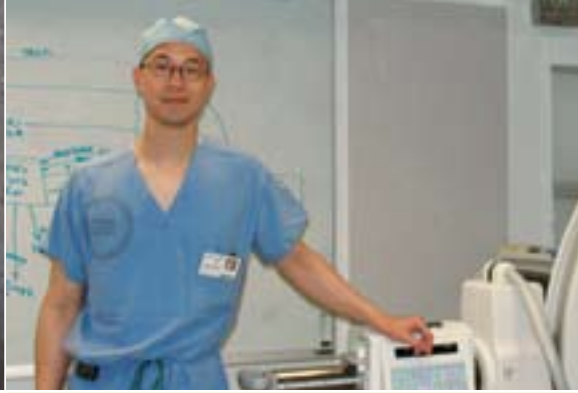
Minimally Invasive Techniques for the Cervical Spine	Indication	Minimally Invasive Procedure
Using specialized tubular retractors and endoscopes that can move through tiny incisions, UCSF neurosurgeons are able to treat cervical spine disorders with minimally invasive surgery.	Herniated discs	Foraminotomy and Discectomy
	Degenerative spinal disease	Foraminotomy Fusion
	Fractures Trauma	Fusion
	Tumors	Decompression Resection

Minimally Invasive Techniques for the Thoracic Spine	Indication	Minimally Invasive Procedure
Cutting-edge minimally invasive techniques for the thoracic spine include treatment for thoracic spinal tumors, which uses three to four small incisions through which the tumor can be removed. The voice-activated AESOP® robotic arm aids in this surgery by following commands and helping to position the thoracoscopic camera for visualization. We are also one of the only centers in the United States to offer minimally invasive transpedicular thoracic discectomies.	Herniated discs with cord compression	Transpedicular discectomy Costotransversectomy
	Fractures Instability	Fusion
	Tumors	Thoracoscopic robotic surgery Posterior resection
	Minimally invasive transpedicular discectomy of the thoracic spine is performed through a tube just 26 mm in diameter.	

Minimally Invasive Techniques for the Lumbar Spine	Indication	Minimally Invasive Procedure
A variety of advanced minimally invasive techniques are also available to treat the lumbar spine.	Herniated discs	Discectomy
	Cauda equina syndrome	Laminectomy
	Spondylosis/ Spondylolisthesis	Anterior lumbar interbody fusion (ALIF) Transforaminal lumbar interbody fusion (TLIF) Posterolateral fusion
	Stenosis	Laminectomy
	Tumors	Resection (with or without fusion)
	Pseudoarthrosis	Revision fusion



Lumbar spine exposure through a minimally invasive lumbar retractor.



Patients with spinal injuries involving the peripheral nervous system are managed in conjunction with the UCSF Nerve Injury Clinic — a multi-disciplinary clinic that includes members of the Departments of Neurological Surgery, Neurology, and Orthopedic Surgery. Comprehensive evaluation and treatments are offered, including non-invasive and surgical management. The Department of Radiology offers support with neurography, among other investigations. Patients are followed until they reach their eventual permanent outcomes.

Patients with tumors affecting the spinal nerves are evaluated and surgically managed. Microsurgical approaches are used along with intra-operative neuromonitoring to achieve aggressive resection with minimal new neurological deficits. Malignant nerve sheath tumors of the extremities are managed in conjunction with members of the Department of Orthopedics who specialize in orthopedic oncology.

Peripheral Nerve

Pain

Patients receive comprehensive assessment of painful conditions, including consideration of direct surgical intervention for their disorder (spine or nerve surgery) as well as consideration of the use of non-invasive, pain-reducing procedures, such as physical therapy or exercises. Surgical procedures include:

- Placement of spinal-cord stimulators
- Implantation of pumps to deliver morphine and other agents directly into the spine
- Percutaneous rhizotomy
- Dorsal root entry zone lesions
- Percutaneous cordotomy for cancer pain

Neuroradiologists may use interventional techniques, such as CT-guided injections, to diagnose and treat pain caused by compression syndromes, such as thoracic outlet and piriformis syndrome (extraspinal sciatica), previous trauma, tumor, infection, or inflammation.

The Neurospinal Disorders Program is one of few programs in California to offer CyberKnife® radiosurgery for the treatment of spine tumors. It is a sophisticated, non-invasive system combining robotics and advanced image-guidance that adjust for a patient's movements and map the precise location of the lesion during treatment. The CyberKnife® offers patients a number of advantages over other therapies:

- Non-invasive, painless treatment
- Treatment in one to five sessions
- Focused radiation that delivers maximum dosage to the target abnormality without impacting healthy tissue
- No need for a frame to immobilize the patient during treatment
- Supplementary therapy after previous radiation

Recent advances in technology also allow tracking of the lesion without implanting fiducials to serve as markers. Radiosurgical navigation with this system has become completely robotic, making the procedure even less invasive.



Radiosurgery

Clinical Research

Artificial Disc Replacement for the Cervical Spine

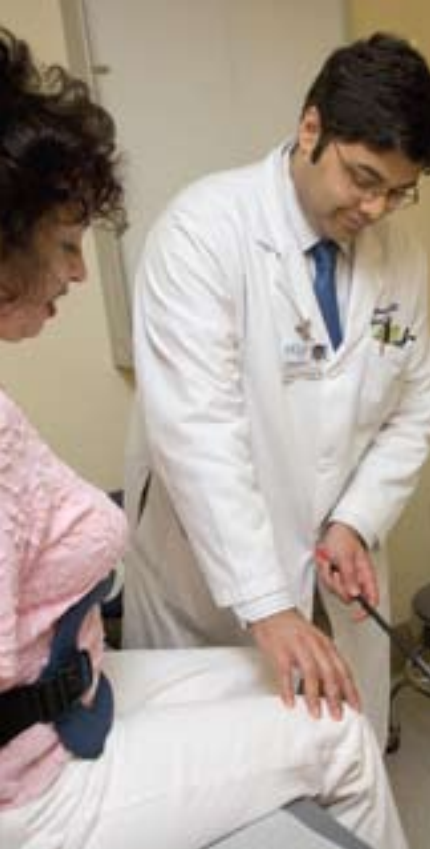Arthroplasty for the cervical spine has recently been made possible by advances in disc replacement technology. In the largest multi-center study ever performed for cervical disc replacement surgery, results demonstrated a distinct advantage for cervical arthroplasty over other treatment options, including improved motion preservation and clinical outcomes. Praveen Mummaneni, MD, was

the lead author of the study, which has been recently published in *Journal of Neurosurgery Spine*. The device will be used to treat herniated discs or spondylosis causing radiculopathy. Dr. Mummaneni serves as a regional instructor for the PRESTIGE® artificial cervical disc.

Artificial Disc Replacement for the Lumbar Spine

Faculty in the Neurospinal Disorders Program at UCSF are leading experts in disc replacement

surgery and have been involved in several trials of arthroplasty for the lumbar spine. Disc replacement may resolve pain resulting from single-level degenerative disc disease without transferring stress to adjacent levels of the spine, preserving a greater range of motion than other treatments. Christopher Ames, MD, serves as a regional instructor for the Charité® artificial lumbar disc, which has the longest clinical experience of any artificial disc and was approved by the FDA in 2004.



- Prospective randomized trial comparing minimally invasive discectomy vs. standard open discectomy. Outcome measures with minimum 6-month follow-up.
- Prospective randomized trial comparing minimally invasive posterior interbody fusion vs. standard open fusion for discogenic back pain. Outcome measures with minimum 1-year follow-up.
- Metastatic cancer to the spinal column: effect of instability and cord edema on outcome.
- Alpha-2 agonists and motor evoked potentials.
- Thoracotomy vs. transpedicular corpectomy for metastatic spinal tumors.
- En bloc vs. piecemeal resection for isolated metastatic spinal tumors.
- Posterior only vs. circumferential surgery for adult degenerative scoliosis.
- Thoracic pedicle subtraction osteotomy vs. vertebral column resection for the correction of fixed regional deformity.

Current Clinical Trials

Publications

Acosta FL Jr, Ames CP. Artificial pedicle screw reconstruction of the cervical spine after lateral paramedian transpedicular approach for lesions of the ventral cervical spinal canal. **Neurosurgery** 2005;57:281-285.

Acosta FL Jr, Thompson TL, Campbell S, Weinstein PR, Ames CP. Use of intraoperative isocentric C-arm 3D fluoroscopy for sextant percutaneous pedicle screw placement: case report and review of the literature. **Spine J** 2005;5:339-343.

Acosta FL Jr, Dowd CF, Chin C, Tihan T, Ames CP, Weinstein PR. Current treatment strategies and outcomes in the management of symptomatic vertebral hemangiomas. **Neurosurgery** 2006;58:287-295.

Acosta FL Jr, Ames CP, Chou D. Operative Management of Adult High-Grade Lumbosacral Spondylolisthesis. **Neurosurg Clin N Am** 2007;18:249-254.

Acosta FL Jr, Aryan HE, Chi J, Parsa AT, Ames CP. Modified paramedian transpedicular approach and spinal reconstruction for intradural tumors of the cervical and cervicothoracic spine: clinical experience. **Spine** 2007;32:E203-210.

Acosta FL Jr, Chi HE, Aryan D, Chou D, Ames CP. Partial spondylectomy: modification for lateralized tumors of the cervical or lumbosacral spine. **J Clin Neurosci**. In Press.

Ames CP, Acosta F, Nottmeier E. Novel treatment of basilar invagination resulting from an untreated C-1 fracture associated with transverse ligament avulsion. Case report and description of surgical technique. **J Neurosurg Spine** 2005;2:83-87.

Ames CP, Bozkus MH, Chamberlain RH, Acosta FL, Papadopoulos SM, Sonntag VK, Crawford NR. Biomechanics of stabilization after cervicothoracic compression-flexion injury. **Spine** 2005; 30:1505-1512.

Ames CP, Smith JS, Preul MC, Crawford NR, Kim GE, Nottmeier E, Chamberlain R, Speiser B, Sonntag VK, Dickman CA. Effect of recombinant human bone morphogenetic protein-2 in an experimental model of spinal fusion in a radiated area. **Spine** 2005;30:2585-2592.

Aryan HE, Sanchez-Mejia RO, Ben-Haim S, Ames CP. Successful treatment of cervical myelopathy with minimal morbidity by circumferential decompression and fusion [published online ahead of print January 11, 2007]. **Eur Spine J**. doi: 10.1007/s00586-006-0291-9.

Aryan HE, Lu DC, Acosta FL Jr, Ames CP. Stand-alone anterior lumbar discectomy and fusion with plate: initial experience. **Surg Neurol** 2007;68:7-13.

Aryan HE, Lu DC, Acosta FL Jr, Ames CP. Corpectomy followed by the placement of instrumentation with titanium cages and recombinant human bone morphogenetic protein-2 for vertebral osteomyelitis. **J Neurosurg Spine** 2007;6:23-30.

Aryan HE, Acosta FL Jr, Ames CP. Two-level lumbar spondylectomy with en bloc dural resection for metastatic renal cell carcinoma. **J Clin Neurosci**. In Press.

Auguste KI, Chin C, Acosta FL, Ames CP. Expandable cylindrical cages in the cervical spine: a review of 22 cases. **J Neurosurg Spine** 2006;4:285-291.

Publications

- Binder DK, Sarkissian V, Dillon WP, Weinstein PR. Spontaneous intracranial hypotension associated with transdural thoracic osteophyte reversed by primary dural repair [Case report]. **J Neurosurg Spine** 2005; 2:614-618.
- Chi JH, Manley GT, and Chou D. Pregnancy-related vertebral hemangioma: case report, review of the literature, and management algorithm. **Neurosurg Focus** 2005;19:E7. <http://www.aans.org/education/journal/neurosurgical/Sept05/19-3-7.pdf>. Accessed August 1, 2007.
- Chou D, Hartl R, Sonntag VK. Conus medullaris syndrome without lower-extremity involvement in L-1 burst fractures: report of four cases. **J Neurosurg Spine** 2006; 4:265-269.
- Chou D, Larios AE, Chamberlain RH, Fifield MS, Hartl R, Dickman CA, Sonntag VK, Crawford NR. A biomechanical comparison of three anterior thoracolumbar implants after corpectomy: are two screws better than one? **J Neurosurg Spine** 2006; 4:213-218.
- Chou D, Smith JS, Chin CT. Spontaneous regression of a discal cyst. Case report. **J Neurosurg Spine** 2007; 6:81-84.
- Deutsch H, Haid RW, Rodts GE, Mummaneni PV. Occipito-cervical Fixation: Long Term Results. **Spine** 2005;30:530-535.
- Fan Y, Liu Z, Weinstein PR, Fike JR, Liu J. Environmental enrichment enhances neurogenesis and improves functional outcome after cranial irradiation. **Eur J Neurosci** 2007;25:38-46.
- Guo L, Quinones-Hinojosa A, Yingling CD, Weinstein PR. Continuous EMG recordings and intraoperative electrical stimulation for identification and protection of cervical nerve roots during foraminal tumor surgery. **J Spinal Disord Tech** 2006; 19:37-42.
- Hartl R, Chamberlain RH, Fifield MS, Chou D, Sonntag VK, Crawford NR. Biomechanical comparison of two new atlantoaxial fixation techniques with C1-2 transarticular screw-graft fixation. **J Neurosurg Spine** 2006;5:336-342.
- Josephson SA, Pillai DR, Phillips JJ, Chou D. Neurosteriosis presenting as cervical myelitis in an immunocompetent patient. **Neurology** 2006;66:1122-1123.
- Lewis AM, Layzer R, Engstrom JW, Barbaro NM, Chin CT. Magnetic resonance neurography in extraspinal sciatica. **Arch Neurol** 2006;63:1469-1472.
- Liu Z, Fan Y, Won SJ, Neumann M, Hu D, Zhou L, Weinstein PR, Liu J. Chronic treatment with minocycline preserves adult new neurons and reduces functional impairment after focal cerebral ischemia. **Stroke** 2007;38:146-152.
- Lu DC, Chou D. Flatback Syndrome. **Neurosurg Clin N Am** 2007;18:289-294.
- Matsumori Y, Hong SM, Aoyama K, Fan Y, Kayama T, Sheldon RA, Vexler ZS, Ferriero DM, Weinstein PR, Liu J. Hsp70 overexpression sequesters AIF and reduces neonatal hypoxic/ischemic brain injury. **J Cereb Blood Flow Metab** 2005; 25:899-910.
- Matsumori Y, Hong SM, Fan Y, Kayama T, Hsu CY, Weinstein PR, Liu J. Enriched environment and spatial learning enhance hippocampal neurogenesis and salvages ischemic penumbra after focal cerebral ischemia. **Neurobiol Dis** 2006;22:187-198.
- Matsumori Y, Northington FJ, Hong SM, Kayama T, Sheldon RA, Vexler ZS, Ferriero DM, Weinstein PR, Liu J. Reduction of caspase-8 and -9 cleavage is associated with increased c-FLIP and increased binding of Apaf-1 and Hsp70 after neonatal hypoxic/ischemic injury in mice overexpressing Hsp70. **Stroke** 2006;37:507-512.
- Mummaneni PV, Rodts GE, Subach BR, Birch BD, Haid RW. Management of thoracic disc disease. **Contemporary Neurosurgery** 2001;23:22:1-8.
- Mummaneni PV, Ondra SL, Haid RW. Principles of spinal deformity – part 2: advances in the operative treatment of thoracolumbar deformity. **Contemporary Neurosurgery** 2002;24:20:1-10.
- Mummaneni PV, Haid RW, Rodts GE. Lumbar interbody fusion: state-of-the-art technical advances. Invited submission from the Joint Section Meeting on Disorders of the Spine and Peripheral Nerves, March 2004. **J Neurosurg Spine** 2004;1:24-30.
- Mummaneni PV, Haid RW. The future in the care of the cervical spine: interbody fusion and arthroplasty. Invited submission from the Joint Section Meeting on Disorders of the Spine and Peripheral Nerves, March 2004. **J Neurosurg Spine** 2004;1:155-159.
- Mummaneni PV, Haid RW. Transoral odontoidectomy. **Neurosurgery** 2005;56: 1045-1050.
- Mummaneni PV, Rodts GE. The mini-open transforaminal lumbar interbody fusion. **Neurosurgery** 2005;57:256-261.
- Mummaneni PV, Deutsch H, Mummaneni VP. Cervicothoracic kyphosis. **Neurosurg Clin N Am** 2006;17:277-287.
- Mummaneni PV, Burkus JK, Haid RW, Traynelis VC, Zdeblick TA. Clinical and radiographic analysis of cervical disc arthroplasty compared with allograft fusion: a randomized controlled clinical trial. **J Neurosurg Spine** 2007;6:198-209.
- Mummaneni PV, Haid RW, Rodts GE Jr. Combined ventral and dorsal surgery for myelopathy and myeloradiculopathy [Review]. **Neurosurgery** 2007;60: S82-S89.
- Quinones-Hinojosa A, Lyon R, Zada G, Lamborn KR, Gupta N, Parsa AT, McDermott MW, Weinstein PR. Changes in transcranial motor evoked potentials during intramedullary spinal cord tumor resection correlate with postoperative motor function. **Neurosurgery** 2005;56:982-993.
- Quinones-Hinojosa A, Robert Kolen E, Jun P, Rosenberg WS, Weinstein PR. Accuracy over space and time of computer-assisted fluoroscopic navigation in the lumbar spine in vivo. **J Spinal Disord Tech** 2006;19:109-113.
- Wang VY, Chou D. The cervicothoracic junction. **Neurosurg Clin N Am** 2007;18:365-371.

How to refer a patient
to the Neurospinal
Disorders Program
of the Department of
Neurological Surgery
at UCSF

**To schedule an
appointment:
1866-81-SPINE**

To schedule an appointment
for CT or MRI: 415-353-2573

To contact our 24-hour
Referral Liaison Service

Phone: 1800-444-2559
Fax: (415) 353-4395
E-mail: Referral.center
@ucsfmedctr.org

To refer a patient who resides
outside the United States,
contact our International
Medical Services

Phone: (415)-353-8489
Fax: (415) 353-8603
E-mail: International@
ucsfmedctr.org

To contact Christopher Ames,
MD, Co-Director, email:
amesc@neurosurg.ucsf.edu

To contact Praveen
Mummaneni, MD,
Co-Director, email:
mummaneni@
neurosurg.ucsf.edu

Neurospinal Disorders Program
at University of California
San Francisco

400 Parnassus Ave., A-311
San Francisco, CA 94143

Visit us on the Web at:
[http://neurosurgery.medschool.
ucsf.edu](http://neurosurgery.medschool.ucsf.edu)

Editor: Ilona Garner

Design: Victoria Maier Magbilang

Illustration: Chris Graalap,
Kenneth Xavier Probst

Photography: Kaz Tsuruta

UCSF Department of Neurological Surgery
505 Parnassus Avenue, M779
San Francisco, CA 94143-0112

Nonprofit Org
U.S. Postage
PAID
University of
California
San Francisco